Adult and Elderly Rhesus Macaque Atlas Template for Functional and Structural Imaging

Kristopher Kosmatka[1], Donald McLaren[1,3], Chris Kroenke[4], John Matochik[6], Donald Ingram[7], Steve Kohama[5], Terrence Oakes[8], Sterling Johnson[1,2]

1 Geriatric Research Education and Clinical Center, Wm. S. Middleton VA Hospital - Madison, WI, 2 Department of Medicine, University of Wisconsin – Madison, 3 Neuroscience Training Program, University of Wisconsin – Madison, 4 Advanced Imaging Research Center, Oregon Health & Science University, 5 Division of Neuroscience, Oregon National Primate Research Center, Oregon Health & Science University, 6 Neuroimaging Research Branch, Intramural Research Program, National Institute on Drug Abuse, 7 Nutritional Neuroscience and Aging Laboratory, Pennington Biomedical Research Center, Louisiana State University System, Baton Rouge, LA, 8 Waisman Center, University of Wisconsin - Madison

INTRODUCTION:

One of the most critical developments in human neuroimaging research has been the creation of standard atlas templates for between participant registration and normalization. These atlases enable alignment of individual scans to improve localization and statistical power of the results, and allow comparison of results between studies and institutions. In non-human primates, such atlases have been constructed for baboons and pig-tailed macaques by Black and colleagues [1]. Presently, however, rhesus macaque (Macaca mulatta) imaging studies have been limited in their generalization by a lack of a common atlas composed from multiple individuals. Thus, we have constructed several rhesus macaque atlases to facilitate future imaging studies.

SUBJECTS:

A large cohort of monkeys were assembled including individuals from the National Institute on Aging (NIA), the Oregon National Primate Research Center at the Oregon Health and Science University (OHSU), and the Wisconsin National Primate Research Center at the University of Wisconsin - Madison (UW). The median lifespan for rhesus macaques has been estimated to be 300 months with a maximum of 480 months. Three atlases are presented here: one composed of 47 adult males (85-258 months, mean age=174.64 mo., st. dev.=29.99 mo.), one composed of 24 elderly males (294-387 months, mean age=335.17 mo., st. dev.=26.75 mo.), and one composed of the polycohort (85-387 months, mean age=228.9 mo., st. dev.=81.7 mo.). See Demographics Table 1 and Figure 1.

IMAGE PROCESSING:

3D object maps were manually drawn to delineate brain from non-brain tissues for each monkey using ANALYZE (Mayo Clinic, MN). The brains were cut at the optic tract at the level of the optic chiasm and at the brain stem inferior to the pons. Binary masks derived from the object maps were used to extract corresponding voxels from the original MRI images to create deskulled images. Each brain was bias corrected for field inhomogeneity using a post hoc segmentation approach using "FAST" in FSL (University of Oxford, Oxford, UK). Each brain was registered to the existing Saleem-Logothetis (SL) single subject atlas space [2] using FSL "FLIRT" (12 parameter linear affine transformation with corratio search cost function). Following alignment, the images were multiplicatively rescaled to a 0-500 intensity range. These images were averaged using FSL and the resulting inital template was then registered into the SL space. All of the original images were then re-registered, this time to the initial template. The individual images were then intensity normalized using a tissue-based linear rescaling approach: mean intensity was measured in a small manually traced region corresponding to white matter in each image, then each image was multiplicatively rescaled to make the mean equal an arbitrary value (300). Finally, for each age group the images were averaged using FSL. Figure 2 shows a schematic of the processing stream.

TABLES AND FIGURES

TABLE 1 - SUBJECT DEMOGRAPHIC MAKEUP

	Adults	Elderly	Polycohort
Subjects (n)	47	24	71
Minimum Age (months)	85	294	85
Maximum Age (months)	258	387	387
Mean Age (months)	174.63	335.16	228.90
Standard Deviation (months)	29.99	26.74	81.69

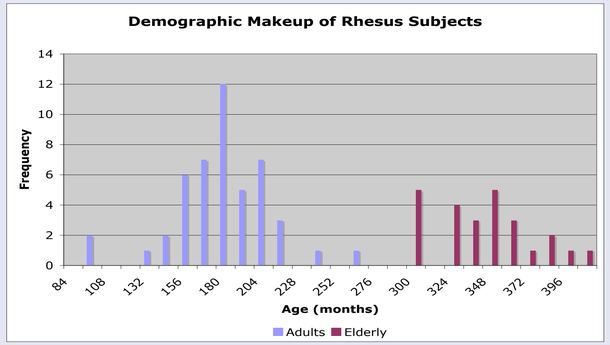

FIGURE 1.
Subject age distribution.

IMAGING PARAMETERS:

NIA:

- GE 1.5 T Signa magnet, surface coil
- 3D T1-weighted SPGR protocol
- TE=6.1 ms, TR=15.2 ms, flip angle=30°
- FOV=10cm, 256x256 aquisition matrix
- 124 transaxial 1mm slices
- .429x.429x.1mm voxels resampled to .429x.429x.429mm

UW:

- GE 3T magnet, quadrature Tx/Rx volume coil 18cm diameter
- 3D T1-weighted SPGR IR prep protocol
- TE=2.1 ms, TR=9.4 ms, flip angle=10.0°
- FOV=160.0mm, 256x256 aquisition matrix
- 124 coronal 0.7mm slices
- 0.6x0.7x0.6mm voxels

OHSU:

- Siemens Trio 3T magnet
- 3D T1-weighted MPRAGE protocol
- TE=4.38, TR=2500
- FOV=12cm, 256x256 aquisition matrix
- 88 coronal 1mm slices
- .46875x.46875x1.0000mm voxels

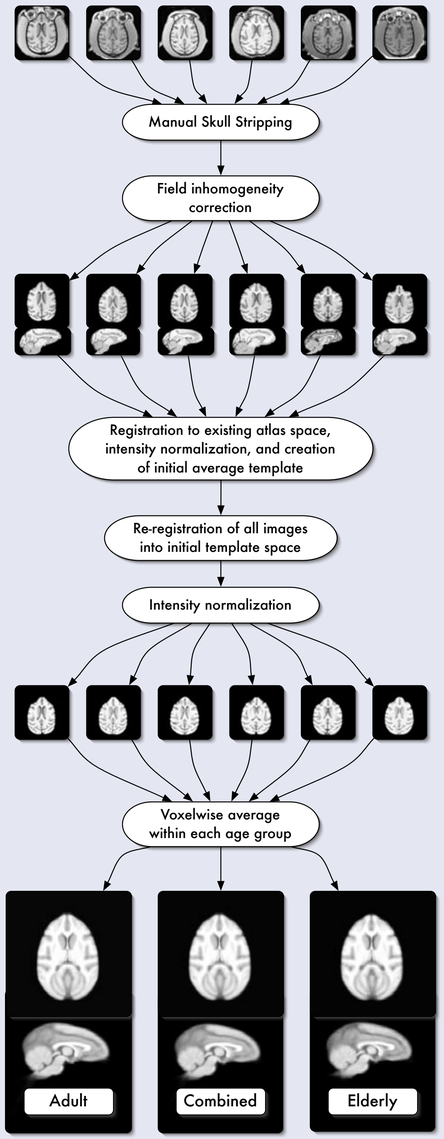

FIGURE 2.
Image Processing Stream.

RESULTS AND DISCUSSION:

The multi-animal atlases presented here are preferable to existing single-animal atlases as the latter is more likely to contain anomalous anatomical features not representative of the general population. However, presenting a multi-animal atlas in the same stereotactic space as the single-animal atlas offers the reliability and validity of normalizing data to a population-based space, while preserving the ability to cross-reference locations in that space to specific anatomical structures in the single-animal. These atlases also improve upon previous multi-animal atlases [1] in several aspects: a much larger cohort, bias corrected images, atlas space native to the species, separation of age and sex groups, and a more commonly studied species model.

The process outlined here can also be generalized to establish a standard method for creating future atlases. Like humans, there are sufficient age and sex related anatomical differences in the rhesus brain to warrant the creation of age and sex specific atlases [3,4]. Such differences suggest that the use of these atlases should be limited respectively to adult and/or elderly male studies. Our collaborative group is working to include females and younger aged animals in our cohort in order to create more atlases including one that would include both males and females across the entire age spectrum. Effective registration and normalization with these atlases has been confirmed in SPM and FSL, enabling integration into established pre-processing fMRI analysis workflows. The atlases will be made publicly available through the SUMSDB [5] and http://www.brainmap.wisc.edu/monkey.html. White and grey matter probability maps are also planned.

REFERENCES:

[1] K.J. Black, J.M. Koller A.Z. Snyder, J.S. Perlmutter, Template Images for Nonhuman Primate Neuroimaging: 2. Macaque, Neuroimage 14 (2001) 744-748.

[2] Saleem, Kadharbatcha S., and Nikos K. Logothetis, A Combined MRI and Histology Atlas of the Rhesus Monkey Brain. Amsterdam: Academic Press, 2007.

[3] M.S. Franklin, G.W. Kraemer, S.E. Shelton, E. Baker, N.H. Kalin and H. Uno, Gender differences in brain volume and size of corpus callosum and amygdala of rhesus monkey measured from MRI images. Brain Res 852 (2000) 263-267.

[4] L. Malkova, E. Heuer, R.C. Saunders, Longitudinal magnetic resonance imaging study of rhesus monkey brain development, Eur J Neurosci 24 (2006) 3204–3212.

[5] SumsDB (Surface Management System Database), Washington University in St. Louis School Of Medicine, 2007, <http://sumsdb.wustl.edu/>