Differentiation of Glioma from Radiation Necrosis by MRI Using Magnetically Labeled Cells

A. S. Arbab[1], A. M. Rad[1], A. Iskander[1], S. L. Brwon[2], S. Panda[3], K. A. Ledbetter[3], G. Ding[3], J. R. Ewing[3], H. Soltanian-Zadeh[1], D. J. Peck[1]

[1]Radiology Research, Henry Ford Health System, Detroit, Michigan, United States, [2]Radiation Oncology, Henry Ford Health System, Detroit, Michigan, United States, [3]Neurology, Henry Ford Health System, Detroit, Michigan, United States

Introduction: Glioma is a central nervous system neoplasm that typically shows hypervascularity, especially in grade III and IV tumors. Unlike the surrounding normal regions of cerebral vasculature, areas of hypervascularity are typically permeable to contrast agents, and can thus be detected by contrast-enhanced MRI or CT. However, areas of radiation necrosis can also show enhancement due to active inflammatory reactions and increasing vascular permeability. Thus, distinguishing recurrent glioma from radiation necrosis becomes problematic if only changes in vascular permeability and/or volume are considered. One distinguishing characteristic, however, is that there is little active angiogenesis at the site of radiation necrosis (1). By determining the differential migration and incorporation patterns of labeled EPCs at the site of glioma, it should be possible to differentiate between radiation necrosis and recurrent glioma. There is evidence of an accumulation of primed dendritic cells and sensitized T-cells at the site of melanoma and glioma, suggesting an initiation of immunity. If intracranial glioma initiates an immunogenic reaction, there should be differential migration and incorporation of magnetically labeled splenocytes (dendritic and T-cells) into these intracranial tumors, but not in radiation necrotic areas, and thus would facilitate differentiation by MRI. Recently, using two FDA-approved agents (ferumoxides and protamine sulfate), we formed a superparamagnetic iron oxide (SPIO)-transfection agent complex. Such complexes can be used to label any kind of mammalian cells (2,3); the labeled cells can then be used as probes to localize physiological and/or pathological processes using MRI for high-resolution images in a clinical setting. To examine whether labeled cells can be used to detect and differentiate physiological and/or pathological conditions, we have selected glioma and radiation necrosis models. It is hypothesized that *in vivo* MR tracking of magnetically labeled cells will enable us to identify different patterns of accumulation and incorporation of injected labeled cells, thus allowing for differentiation between recurrent glioma and radiation necrosis.

Methods: Double Labeled (SPIO and dye DiI) human EPCs or rat splenocytes were injected intravenously in rats bearing an intracranial human glioma (U251 in nude rats) or gliosarcoma (9L in Fisher rats), respectively. Cells were also injected in rats with radiation injury (75 Gy irradiation at 3 mm right to bregma). Cells were injected 7 days after tumor implantation or irradiation and MRI was obtained on day 7 after the injection of cells (day 14). Multiecho T2-weighted (TEs of 10, 20, 30, 40, 50 and 60 msec and a TR of 3000 msec, 32 mm FOV, 1 mm slice thickness, 256x256 matrix, and NEX = 2), multiecho T2*-weighted (TEs of 5, 10, 15, 20, 25, and 30 msec and a TR of 3000 msec, 32 mm FOV, 1 mm slice thickness, 256x256 matrix, and NEX = 2) and 3D gradient echo (TR=100 msec, TE=9 msec, 10º flip angle, 32x32x16 mm^3 FOV, 256x192x128 matrix, and NEX = 1) MRI were obtained by a 7 Tesla MR system (Magnex Scientific, Abingdon, England) interfaced to a Bruker Avance console (Bellerica, MA). Following in vivo MRI, rats were euthanized and then perfused with PBS and 3% paraformaldehyde. Randomly selected rat brains were also underwent *ex vivo* high resolution MRI. Collected whole brains were further fixed in 3% paraformaldehyde mixed with 30% sucrose for 24 hours and snap frozen for frozen sectioning. Brain including tumor was sectioned at 20 µm thickness at every 200 µm interval. Sections were stained for blood vessels using FITC labeled lectin, and presence of CD31 and vWF using anti human monoclonal antibodies against human CD31 and vWF. Prussian blue staining was performed to detect the iron positive cells. For radiation injury models, brain sections were stained for iron and counter stained with nuclear fast red. Blood vessels in the normal and irradiated brain were outlined by FITC labeled tomato lectin. Distribution of blood vessels and pattern of neovascularization at the site of radiation were compared with that of implanted tumor and surrounding brain.

Results: Both *in vivo* and *ex vivo* MRI showed low signal intensity areas at the margin of the tumors in rats injected with labeled cells (both EPCs and splenocytes, Figure 1). Iron positive cells were present at the corresponding sites of low signal intensities seen on MRI. There were also CD31 and vWF positive cells at the corresponding site of iron positive cells (injected with EPCs). Fluorescent microscopy showed DiI positive cells forming new vessels. There was no definite low signal intensity area indicating accumulated iron positive cells (either EPCs or splenocytes) seen at the site of radiation injury and Prussian blue staining also did not show any iron positive cells (Figure 2). Vascular density as well as vascular pattern in irradiated area has not changed compared to that of control brain (Figure 3).

Conclusion: By targeting angiogenesis or immunogenecity, it is possible to differentiate glioma from radiation necrosis using magnetically labeled cells (EPCs or T-cells) and MRI.

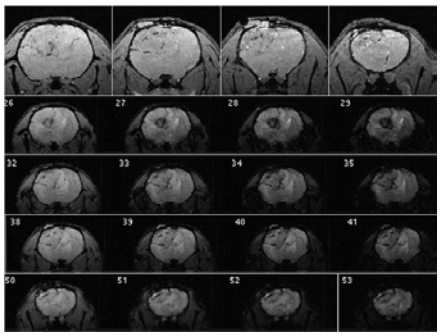

Figure 1 *shows in vivo 3D (upper panel) and multiecho (10, 15, 20 and 25 ms, left to right) gradient echo MR images (lower 4 panels). Each row of gradient echo images correspond the sections (left to right) of 3D images. There are low signal intensity areas around the tumor indicating migration and homing of labeled EPCs.*

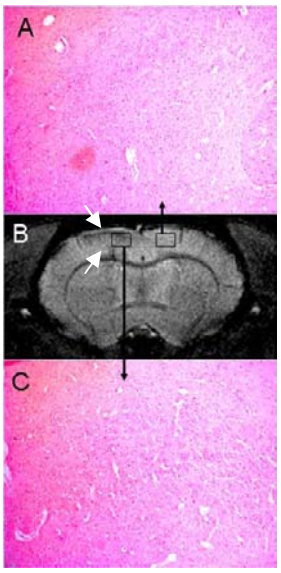

Figure 2 *shows MRI of brain (B) from irradiated rat injected (intravenously) with labeled splenocytes and Prussian blue stained sections corresponding to normal brain area (A) and the area corresponding to radiation injury (C). Note the low signal intensity on MRI at right cortical area (white arrows, B). Prussian blue stained section (x20 magnification) showed no iron positive cells either at normal brain (A) or corresponding radiation injured (C) areas. Although no definite change has been observed in the distribution of cells or blood vessels (**see Figure 3**), there are a few clear spaces seen at the area of radiation injury.*

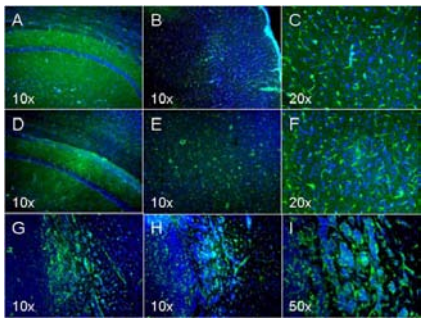

Figure 3. *Distribution of blood vessels in normal brain (A,B,C), or in areas of radiation injury (D,E,F) and pattern of vascularization in tumors (G,H,I). Despite irradiation there were no significant changes in the vascular distribution between normal and radiation injured brain. However, there were marked differences in the vascular distribution as well as vascular morphology in the tumor and its surrounding brain. Compared to normal brain or radiation injured areas, formation of blood vessels in the tumor and its surrounding areas was not well demarcated. Blood vessels (endothelial lining) were outlined by FITC labeled tomato lectin (green dots and lines) and the nucleuses were depicted by DAPI staining (blue dots).*

References: (1) Munter et al. Radiology 1999; 212:475-482. (2) Arbab et al. Blood 2004; 104:1217-1223. (3) Arbab et al. Transplantation 2003; 76:1123-1130.