Late Development of the Superior Longitudinal Fasciculus Revealed by Diffusion Tensor Imaging (DTI)

J. Zhang[1], A. C. Evans[2], L. Hermoye[3], P. Donohue[4], S. Wakana[1], W. Zhang[1], M. I. Miller[5], P. C. van Zijl[1,6], S. Mori[1]

[1]Radiology, Johns Hopkins University School of Medicine, Baltimore, MD, United States, [2]McConnell Brain Imaging Centre, Montreal Neurological Institute, Montreal, QC, Canada, [3]Diagnostic Radiology Unit, Univerisity Catholique de Louvain, Saint-Luc Univerisity Hospital, Brussels, Belgium, [4]Division of Neonatology, Johns Hopkins School of Medicine, Baltimore, MD, United States, [5]Center of Imaging Science, Johns Hopkins University, Baltimore, MD, United States, [6]F.M. Kirby Functional Imaging Center, Kennedy Krieger Institute, Baltimore, MD, United States

Introduction: Development of axonal pathways is known to be highly complicated but well organized. Most of the pathways are established during embryonic and fetal life in the human. Little is known about how much axonal growth or rearrangement is taking place in situ postnatally. We applied DTI to 82 subjects, ranging from newborn to adult. DTI can provide rich information about white matter anatomy throughout the development process in a non-invasive manner and it is of great interest to use DTI to quantitatively characterize the white matter development in terms of morphological (size and shape of tracts) and contrast changes (FA and ADC).

In this study, images from multiple subjects were normalized to the Montreal Neurological Institute (MNI) single subject template using 12-parameter affine transformations to remove variations in global scaling, orientation and position. The results demonstrated active formation of association pathways during the first two years. They also suggested that the development of the superior longitudinal fasciculus (SLF) lagged that of other association fibers.

Methods: Images of 82 subjects were taken from our human brain image database (1). Subject age ranges from newborn to adult (~20-40 years old). Subjects were arranged into 7 age groups. The numbers of subjects in each group are: newborn (n=8), 1 year (n=7), 2 year (n=12), 3-5 year (n=9), 6-10 year (n=8), 11-19 year (n=8) and adult (n=30). Subjects over 3 months and under 5 years old were patients with clinical indications who had normal MRI and were labeled as "Quasi-Normal". All images were normalized to the MNI single subject template using 12-parameter affine transformation provided by the automated image registration (AIR) software (2). The transformations were computed using average diffusion weighted images as inputs. Tensor images were normalized using these transformations (3) and averaged (4). After normalization, voxel by voxel comparisons on white matter FA, ADC and orientation between the adult group and each pediatric group were performed. To detect change in the orientation of the primary eigenvector (V_1) in a pixel, we computed the smallest angle (α) between the V1 of the pixel in a normalized subject image and the V1 of the same pixel in the average adult brain images. For each voxel, values of FA, ADC and α from all subjects in a pediatric group ($n \geq 7$) were compared to values from the adult subjects ($n = 30$) using the Wilcoxon Rank-Sum test.

Results and Discussion: Normalization of tensor images from all subjects to the MNI template placed them in a common coordinate system (Fig. 1). Several studies have described significant changes in FA and ADC of white matter tracts during development (1,5). Normalization facilitates quantification of such comparisons. Figure 2A-B show areas with significant difference in ADC and FA values between normalized newborn and adult brains. ADC in most brain regions decreased significantly from birth to adult, while FA in most white matter regions increased significantly, in line with expectations on further pathway development and myelination.

Development of WM morphology was studied via examination of the average diffusion tensor images at different age. All major white matter bundles that can be imaged by DTI in the adult could also be found in newborn babies and, for most of them,the morphologies did not change much with age. This observation suggests that growth of these WM tracts had approximately the same rate as the growth of the entire brain. One of the most notable exceptions was the SLF. In Fig. 1, the boundary of adult SLF is overlaid on images from earlier stages to demonstrate changes in its morphology. In images of newborn babies, the size of SLF was significantly less than its mature form. As brain matures, average DT images show gradually enlarged SLF. This finding was confirmed by examination of original individual images, i.e., it was not an artifact due to mis-alignment in the normalization step. This observation is also confirmed in Fig. 2C, in which the large part of the regions occupied by adult SLF shows significant changes in tissue orientation (V1), from medial-to-lateral (red) to anterior-to-posterior (green). At the current imaging resolution, SLF is the most prominent pathway that had significant changes in orientation. This change is likely due to rapid growth of axonal fibers in the SLF region in the neonatal period. The results suggest that SLF is one of the slowest maturing white matter tracts.

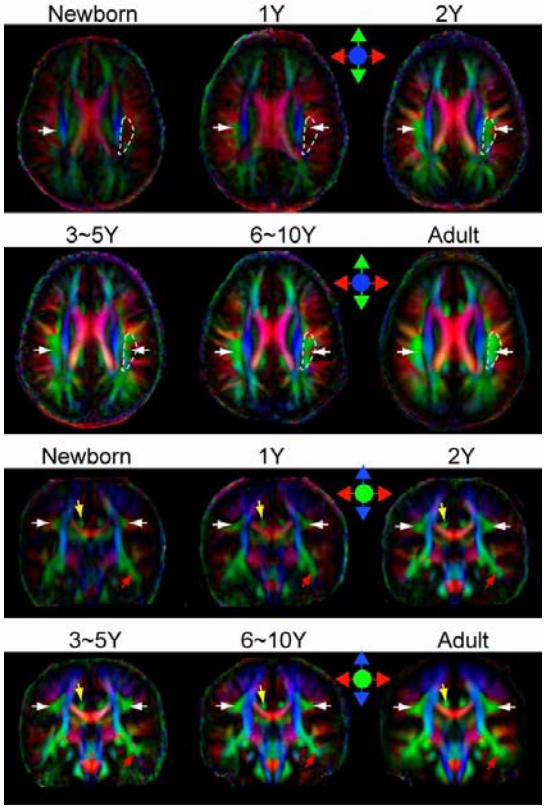

Fig. 1: Axial and coronal color maps of the developing brain in MNI coordinates. Images were constructed from our average tensor data sets. The boundary of right SLF in adult brain was manually defined and overlaid in all images. The location of SLF (white arrow), cingulum (yellow arrow) and IFO (red arrow) are indicated. Note the directional encoding indicated with the color arrows. Images of 1Y, 2Y and 3~5Y are Quasi-Normal (see text).

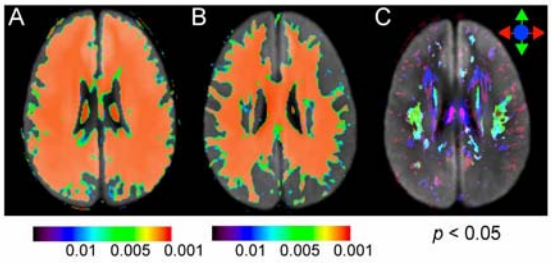

Fig. 2: Statistical Maps showing significant changes in ADC (A), FA (B) and tissue orientation (C) as measured by α between newborns and adults in the same axial slice shown in Fig. 1. In A and B, p values are overlaid on average diffusion weighted images of adult brains. In C, regions with significant change in V1 ($p<0.05$) are highlighted and colored according to the orientation in the average adult brain image for ease of identification.

References:

1). L. Hermoye et al., NeuroImage, In press.
2). R.P. Woods et al., J. Comp Assis Tomo, 22, 1998, pp. 139-152
3). D. Xu et al., Magn Res Med, (50)-1, 2003, pp. 175-182
4). D. Jones et al., NeuroImage, (17)-2, 2002, pp. 592-617
5). L. Snook et al., NeuroImage, (26)-4, 2005, pp. 1164-1173