Prognostic power of DCE-MRI heterogeneity analysis in patients with advanced solid tumours

Y. Watson[1], S. Cheung[1], C. Roberts[1], G. A. Buonaccorsi[1], K. E. Davies[1], A. Jackson[1], C. Ton[2], L. Broughton[2], F. Power[2], G. C. Jayson[2], Z. Lang[3], S. Mullamitha[2], R. Beckman[3], G. J. Parker[1]

[1]Imaging Science and Biomedical Engineering, University of Manchester, Manchester, United Kingdom, [2]Cancer Research UK Dept. Medical Oncology, Christie Hospital, Manchester, United Kingdom, [3]Centocor, Malvern, PA, United States

Introduction Quantitative T_1-weighted dynamic contrast-enhanced MRI (DCE-MRI) has the potential to provide physiological information relating to the functional status of tissue microvasculature[1]. We explored the potential for measurements of the heterogeneity of DCE-MRI parameterisations to provide prognostic value in patients with advanced solid tumours in a phase I study of CNTO95, a fully human monoclonal antibody against the α integrins. Whole-tumour regions of interest (ROIs) were used to derive summary statistics and histograms[2] of time course parameterisations. Histogram analysis showed clear evidence for differences between patients with progressive disease from those with stable or better disease. In contrast, summary statistical analysis showed little evidence for such differentiation.

Patients 22 patients with advanced cancer demonstrating abdominal or pelvic masses were enrolled in a multi-visit DCE-MRI study to assess the efficacy of this novel anti-vascular treatment. Following informed consent patients underwent screening investigations and if satisfactory they were allocated sequentially to cohorts of 3 patients receiving 0.1, 0.3, 1, 3 and 10 mg/kg on days 0, 28, 35 and 42. DCE-MRI investigations were performed at baseline (up to 1 week prior to dose) and on days 1, 7, and 49. For the purposes of this study, tumour progression was defined as a significant increase in tumour volume (greater than the single patient 95 % confidence interval), as measured by MRI on day 49 (Fig. 1). A tumour showing no significant increase in tumour volume was considered to have 'stable or better' disease.

Data All data were acquired on a 1.5 T Philips Intera system. The baseline T_1 measurement consisted of 3 axial spoiled Fast Field Echo (gradient echo) volumes with flip angles 2, 10, 20 degrees, respectively and 4 signal averages. The dynamic series was acquired using the scanner whole body quadrature coil for transmission and reception. The dynamic series consisted of 75 consecutively-acquired axial volumes with a flip angle of 20 degrees, 1 signal average, and a temporal resolution of 4.97 s. All studies maintained the same number of slices (25), field of view (375 mm × 375 mm), matrix size (128 × 128), TR (4.0 ms), and TE (0.82 ms) for the baseline T_1 measurement images and the dynamic series itself. Slice thickness was 4 mm for small target lesions or 8 mm for larger lesions, giving a superior-inferior coverage of 100 mm or 200 mm, respectively. ROIs were defined in 3D on co-registered high resolution T_1- and T_2-weighted volumes to encompass the entire tumour of interest.

Time series parameterisation The kinetic model parameters K^{trans}, v_e, and v_p, determined using a generalised version of the Kety model[3], and the model-free parameter *IAUC*[4] were measured within the ROI. All parameters were determined voxel-by-voxel.

Region of interest summary statistics Median and mean values of *IAUC*, K^{trans} v_e, and v_p were determined from the enhancing portion of each tumour ROI. No effect that could be attributed to CNTO95 was observed in any individual patient or cohort. The Mann-Whitney U test was used to test for parameter differences across all data (combining the results of all cohorts and all visits) that distinguished between the progressive and stable/better patient groups. K^{trans} was found to be slightly (mean difference 0.042 min^{-1}) but significantly lower in the group that showed stable or better disease ($p = 0.039$, 2-tailed). *IAUC*, v_e, and v_p showed no significant difference.

Histogram analysis Volume-normalised histograms for each parameter were constructed from the voxel values in enhancing tumour using 20 bins of equal dimension, ranging from zero to heuristically-defined maximum values. An additional bin was assigned to capture voxels with values greater than this maximum. The Mann-Whitney U test was applied to each bin of each parameter to test for differences across all pooled data (again combining the results of all cohorts and all visits) that distinguished between the progressive and stable/better patient groups. Widespread large and highly statistically significant differences were observed in all parameters. The differences between the groups in the mean K^{trans} histograms are shown in the figure, indicating that the peak in the K^{trans} distribution is at higher values in the progressing tumour group. Other parameters demonstrated similar differences between the stable disease and progressive disease groups (data not shown).

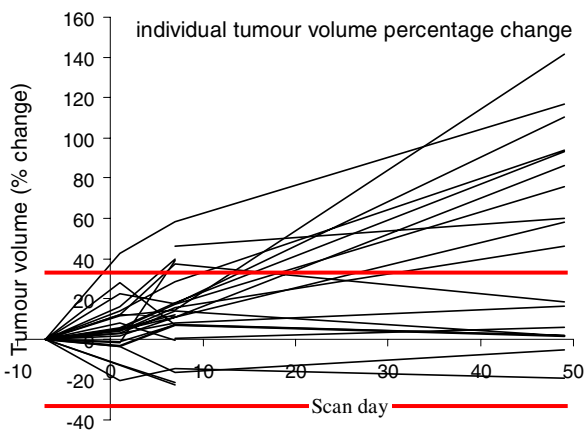

Figure 1. *Change in tumour volume. Red lines indicate 95 % confidence intervals for a measured change in an individual tumour.*

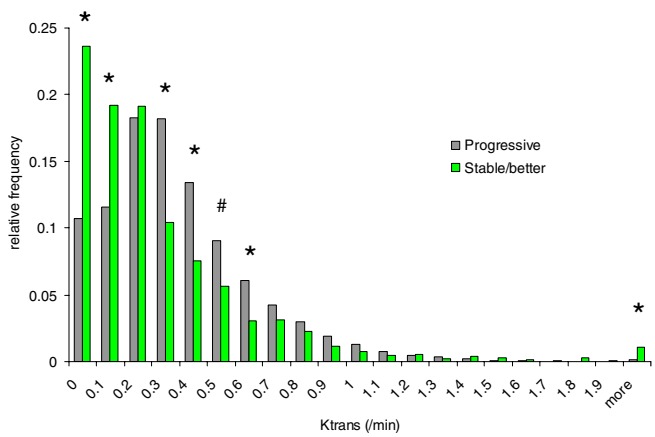

Figure 2. *Histogram demonstrating group mean differences in tumour k^{trans} values between the progressive (grey) and stable/better (green) groups. *Indicates differences between groups at the $p \leq 0.001$ level; # indicates $p \leq 0.002$.*

Discussion 3D tumour growth analysis at day 49 allowed us to identify two patient sub groups showing stable/better or progressive disease. Categorisation into these two groups appeared not to be treatment dependant as they included patients from all cohorts. Similarly, there was no observed relationship between dose of CNTO95 and DCE-MRI parameter changes. Pooling all the data from the study allowed differences in the DCE-MRI parameters between the groups to be related to status at day 49. Summary statistics show a small significance difference between the groups in K^{trans} only, but widespread significant differences in the normalised histograms of all DCE-MRI parameters. Our interpretation of these findings is that the differences observed in the histogram analyses are independent of any drug effect, and that they therefore may indicate general prognostic utility. The fact that this information is largely invisible to summary statistic analysis indicates the importance of investigation of information regarding tumour heterogeneity, such as histograms, when interpreting the results of any DCE-MRI study.

References

1. Jackson, A., *et al.*, "Dynamic contrast-enhanced magnetic resonance imaging in oncology," in *Medical Radiology Diagnostic Imaging*, A. L. Baert and K. Sartor, Eds. Berlin: Springer, 2005, pp. 311.
2. Hayes, C., *et al.*, *NMR Biomed.*, 15, 154, 2002.
3. Tofts, P.S., *J. Magn. Reson. Imag.*, 7, 91, 1997.
4. Evelhoch, J.L., *J. Magn. Reson. Imag.*, 10, 254, 1999.