Quantitative cerebral blood volume measurement using the Bookend Method : water exchange effect correction and diagnosis on tumor in gradient-echo and spin-echo EPI

W. Shin[1], S. W. Horowitz[2], T. A. Cashen[1], T. J. Carroll[1,2]

[1]Biomedical Engineering, Northwestern University, Chicago, IL, United States, [2]Radiology, Northwestern University Feinberg School of Medicine, Chicago, IL, United States

Introduction: Parameters related to tissue perfusion have been shown to reflect underlying pathophysiology of a number of diseases. For example, cerebral blood volume (CBV) has been used in the diagnosis of cerebrovascular occlusive disease, ischemic stroke, tumor neovascularity, neoplasia and Alzheimer's disease. In recent years, MR imaging techniques have been developed to create parametric images of CBV quantification of CBV using MR imaging has remained challenging. We have developed an imaging protocol and mathematically algorithm to quantify CBV in the presence of intravascular/extravascular water exchange. Initial results in a method to create whole brain quantitative CBV maps which are independent of water exchange effects are presented.

Methods

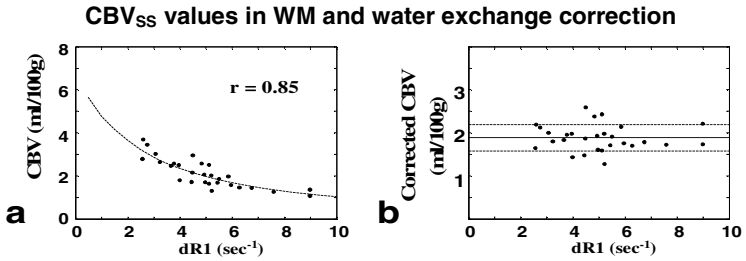

Figure 1. (a) CBV_{SS} values in WM from 28 patients, and the fitted CBV curve for $1/\tau=1.1sec^{-1}$.(b) CBV values corrected for water exchange were 1.88±0.31 ml/100g, in agreement with PET data.

Bookend method and water exchange correction: CBV can be measured using two complimentary methods: dynamic susceptibility contrast (CBV_{DSC}) and static steady state T_1 changes (CBV_{SS}). Both techniques require the injection of a contrast agent. CBV_{DSC} measurements produce relative CBV (rCBV) values rather than the quantitative albeit time consuming CBV values of CBV_{SS}. We have implemented the "Bookend Method" which combined CBV_{SS} and CBV_{DSC} images to quantify CBV. By inserting a fast single slice T_1 measurement before and after a CBV_{DSC} measurement [1], we are able to calibrate $rCBV_{DSC}$ to produce whole brain quantitative CBV_{DSC} images. Although the CBV_{SS} method has the potential to measure qCBV, water exchange effects create a measurement of bias (Figure 1) which prohibits accurate calculation of qCBV. We have derived a correction algorithm that can effectively determine the water exchange rate, providing a means for analytical removal the water exchange measurement bias.

Imaging Protocol: The water exchange rate of normal tissue was determined from a set of 28 consecutive patients scheduled for follow-up MR perfusion exams to rule out tumor recurrence (male: 9, female: 19, mean age = 51.9 ± 15.9 years). We have developed a single slice, multi-phase, segmented Look-Locker echo planar (LL-EPI) sequence for rapid T_1 quantification : FOV= 220×220 mm, slice thickness = 5 mm, nonselective inversion pulse, TR/TE = 21/9.9 ms, 21 lines per segment, flip angle = 20°, 120 phases, delay time = 2 sec, total scanning time = 45 sec. For CBV_{DSC} images we employed both Gradient Recalled Echo (GRE) and Spin Echo (SE) single shot, multiphase scans to test the hypothesis that SE-perfusion scans can be used to determine whole brain qCBV.

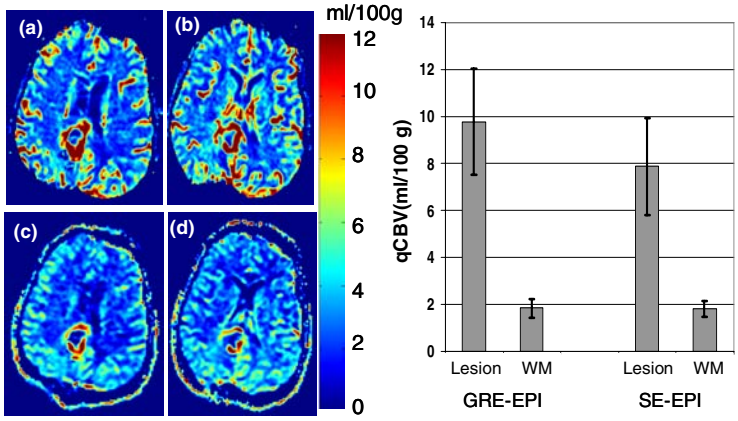

Figure 2: A comparison of quantitative Gradient Echo EPI CBV images (a,b) and Spin Echo qCBV images (c,d) of the same lesion. Significant differences (p<0.001) exist between the lesions and normal WM. A comparison of mean qCBV in confirmed tumors and normal WM from a series of patients shows a systematic, yet non-significant difference in SE and GRE qCBV values.

In a second set of 8 consecutive patients with pathologically confirmed tumors, qCBV was measured prior to surgical resection to test the hypothesis that quantification vascular proliferation with perfusion MRI is possible and can be used to identify cancerous lesions. QCBV was measured in white matter (WM) and pathologically confirmed gliomas (n= 4) and meningiomas (n = 4) using standard techniques [2]. Mean qCBV values were compared using a Students t-test with significance defined at the 5% level.

Result: In normal WM we find that in the fast exchange model, experimental data indicated the water exchange rate of $\tau=11$/sec, yielding a corrected qCBV of 1.88 +/- 0.31 ml/100g. This technique was applied in pre-operative patients where we find normal WM, which is used as a reference for tumor grading [cha] to be 1.84 +/- 0.80 and 1.80+/- 0.70 using GRE and SE- respectively. No significant differences existed between GRE and SE qCBV values. In tumors, the mean value of CBV was 9.78 +/- 4.53 ml/100g and 7.87 +/- 0.70m ml/100g for GRE and SE respectively (p<0.001).

Conclusion / Discussion: Our water exchange corrected CBV_{SS} value in WM, agree with PET CBV values (1.8~2.0 ml/100g). The bookend method with a water exchange correction has shown the potential to quantify CBV values and to quantify vascular proliferation, a key parameter in tumor staging.

Reference

1. Sakaie *et al. JMRI* (2005)

2. Soonmee Cha, *the 4th international Symposium on Brain Perfusion* (2005)