Cerebral magnetic resonance angiography of the mouse lemur Primate

N. El Tannir El Tayara[1], F. Aujard[2], J. L. Picq[3], A. Volk[1], M. Dhenain[1,4]

[1]Institut Curie, Orsay, France, [2]CNRS UMR 5176, Brunoy, France, [3]Paris 8 university, EA 2027, Saint-Denis, France, [4]CEA-CNRS URA 2210, Orsay, France

Introduction: Time of Flight (TOF) MR angiography is a non invasive method that can be useful to describe the cerebrovasculature of animals, especially if they are precious. In our study, we set-up a protocol to detect cerebral vessels in mouse lemurs (*Microcebus murinus*), one of the most primitive Primate measuring 12 cm and weighting 80 g. This animal has a smooth brain and is used as a model of cerebral aging (1). Several atlases of its brain have been published (2, 3), but its vasculature has never been described until now. The protocols used for TOF acquisition in mouse lemurs were compared to protocols used in rodents (mice and rats) and the angiograms from the three species were compared.

Materials and methods: In vivo cerebral MR angiograms were recorded on a 4.7T Bruker Biospec system using a surface coil actively decoupled from the transmitting birdcage probe. Three dimensional gradient echo sequences were used to record angiograms from mice, rats, and mouse lemurs (TR=19ms, TE=4.4ms, flip angle (α)=30°, acquisition matrix: 144x192x104, field of view (FOV): 15x20x15mm^3 for mice and 20x20x20mm^3 for rats and lemurs). Two dimensional gradient echo sequences were also used to record angiograms from rats and mouse lemurs (TR=30ms, TE=3.9ms, α=60°, FOV: 23x23mm^2, slice thickness=0.4 mm (85 slices overlapped by 0.2mm), acquisition matrix: 192x192). Brain tissues were manually extracted using Amira® software and angiograms were obtained by generating Maximum Intensity Projections (MIPs).

Results: Two dimensional TOF angiograms from mouse lemurs and rats allowed to detect several arteries and veins. Three dimensional TOF angiograms only displayed arteries. Veins could not be detected because of their low flow velocity. Three dimensional TOF angiograms from mouse lemurs displayed only few arteries with respect to rodents. On 2D acquisitions, several vessels could be detected in mouse lemur angiograms and named by comparison to those detected on 3D acquisitions from rodents (figure).

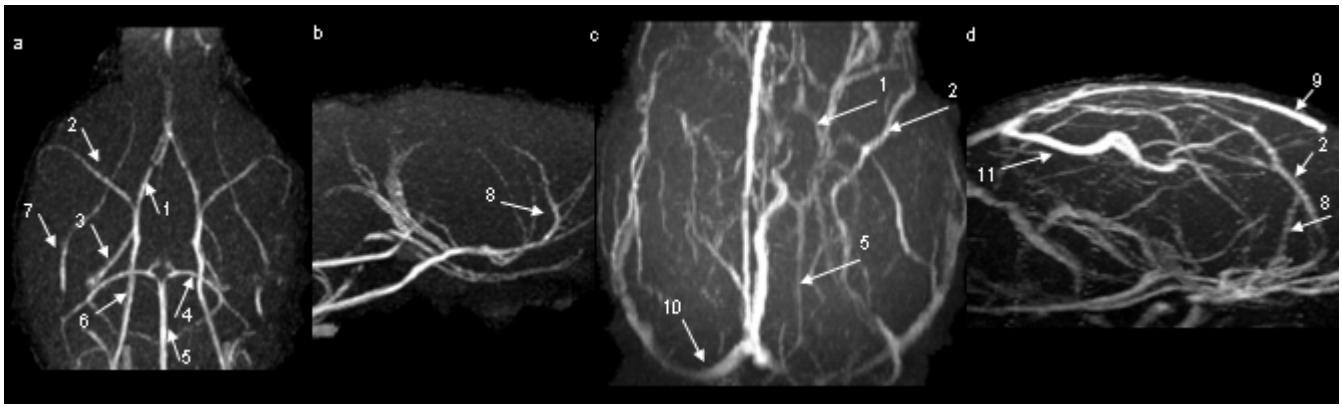

Figure: Mouse angiogram acquired with a 3D gradient echo sequence (a: horizontal; b: sagittal views) compared to mouse lemur angiogram acquired with a 2D gradient echo sequence (c: angiogram rotated by 24° with respect to the horizontal direction; d: sagittal view). Annotations: Arteries: 1. anterior, 2. middle, 3. posterior cerebral arteries, 4. superior cerebellar artery, 5. basilar artery, 6. internal carotid artery, 7. pterygopalatine artery, 8. azygos anterior cerebral artery; Veins: 9. superior sagittal sinus, 10. transverse sinus, 11. straight sinus.

Conclusion/Discussion: This study showed that MR angiography methods are useful to describe the vascular system of precious animals such as the mouse lemurs. 2D TOF techniques yielded better results in mouse lemurs than 3D techniques that displayed only few arteries, probably because of the relatively low cerebral flow velocity in these animals. Angiograms from lemurs and rodents displayed several similarities with respect to the disposition and extend of most vessels however some differences, such as a smaller circle of Willis in lemurs could be highlighted.

References: 1. Dhenain M et al. Magnetic Resonance In Medicine 2003;50:984-992. **2.** Le Gros Clark WE. Proceedings of the Zoological Society of London 1931:463-485. **3.** Bons N et al. Brain Research Bulletin 1998;46(1, 2):1-173.

Acknowledgments: This study was funded by Longevity GIS, the aging ATC (INSERM), the French 'Federation for Brain Research', and the 'Neuroscience ACI research' programs from the French Minister for Research.