Effect of Diabetes on the Renal Medullary Oxygenation in Rats: an Early Time Course Study

E. Santos[1], L-P. Li[1], L. Ji[1], P. V. Prasad[1]

[1]Radiology/CAI, Evanston Northwestern Healthcare, Evanston, IL, United States

INTRODUCTION: Diabetes mellitus is a leading cause of end-stage renal disease (ESRD). The pathogenesis of diabetic nephropathy is not yet well understood [1]. At the onset of diabetes mellitus, the intrarenal hemodynamic abnormalities manifest in the form of glomerular hyperfiltration [2] and high oxygen consumption [3], the factors that may be responsible for the onset and progression of diabetic nephropathy [4]. Most of the experimental investigations to-date have been made in the streptozotocin (STZ)-induced diabetes model. Changes in renal oxygenation have been shown at four weeks [5] by invasive microelectrode measurements and as early as five days by non-invasive BOLD (blood oxygenation level dependent) MRI measurements [6]. BOLD signals correlate with tissue pO_2 because of its sensitivity to deoxyhomoglobin content. We have used BOLD MRI to evaluate intra-renal oxygenation levels under normal conditions and during physiological and pharmacological maneuvers in both human and rats [7-16]. In this study, BOLD MRI measurements were performed to evaluate early changes in diabetic rat kidney. In addition, renal medullary blood flow and pO_2 were measured regionally using invasive OxyLite (a pO2 monitor) and Oxyflo (a blood flow monitor) (Oxford Optronics, Oxford, UK).

METHODS: ***Animals*.** Diabetes was induced in Wistar Furth rats (Harlan Lab, Madison, WI, USA) by an injection of STZ (Sigma, USA, 50-55 mg/kg) *via* the lateral tail vein under light anesthesia using isoflurane (Abbott Laboratories, North Chicago, IL, USA). Control rats received vehicle. Animals were housed at the institutional animal care facility and had free access to food and water. Protocols were approved by the Institutional Animal Care and Use Committee. Animals were divided into Oxylite and BOLD MRI groups. Each group was then subdivided into: control, 2-, 5-, 14-, and 28-days post induction of diabetes. Multiple comparisons were performed using ANOVA followed by the Dunnett and Tukey posttest (Prizm 4, GraphPad Software, Inc, San Diego, CA, USA). A p value ≤0.05 was considered statistically significant.

Protocol 1: Evaluation of BOLD MRI signal in the outer medulla (OM). The anesthetized rats were placed in a standard knee coil. Multiple gradient recalled echo images were obtained using 3.0 T whole body scanner (CV/i, GE, Milwaukee, WI, USA, TR/TE/Flip angle/bandwidth/slice thickness = 70/4.4-57.8ms/30/41.7 kHz/2mm) with an in-plane resolution of 0.4 mm x 0.4 mm. The rate of spin dephasing R2* (=1/T2*) was used as a BOLD parameter, which was calculated by fitting a single exponential function to the signal intensity *vs.* echo time data. Approximately 10 ROIs, including at least 4 pixels, were placed in medulla and cortex on the R2* map using anatomic image as a reference. An increase in R2* implies a decrease in tissue pO_2.

Protocol 2: Evaluation of outer medullary blood flow (OMBF) and oxygen tension (pO_2). After anesthesia (ketamine, 60-100 mg/kg *i.m.* Abbott Laboratories, North Chicago, IL, USA and Inactin, 100 mg/kg *i.p.*, St. Louis, MO, USA), saline with 2% albumin was administered at a rate of 500µl/h/100g for control rats and double for diabetic rats (diabetic rats have a higher loss of fluid) in the femoral vein. The left kidney was exposed and immobilized in a stainless steel cup. The body and kidney temperatures were monitored. Microprobes were inserted into the kidney at 3 to 4 mm depth to reach the renal outer medulla using a micromanipulator. The pO_2 and blood flow signal from the combined OxyLite/OxyFlo probe was recorded in Chart 5 (Powerlab, AD Instruments, Colorado Springs, CO, USA).

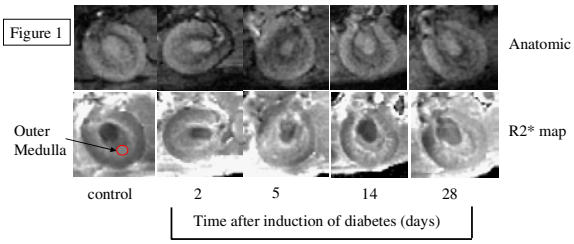

RESULTS:

Figure 1. Effect of diabetes on the BOLD MR images. R2* maps from one representative rat from each group: control, 2-, 5-, 14- and 28-days. Note the increase in brightness on the R2* maps with time after STZ, suggesting increasing levels of hypoxia.

Figure 2. Summary of pO2, blood flow and R2* measurements as a function of time after STZ. Error bars show the standard error over different animals within each sub-group. Outer medullary pO_2 (a), blood flow (b) were measured in control rats (non-diabetic) (n = 6), 2-(n = 6), 5- (n = 6), 14- (n = 6) and 28-days (n = 5) after induction of diabetes. Effect of diabetes on the renal R2* signal (c) in the outer stripe of outer medulla (OSOM) were measured in a second group of control rats (n=6), 2-(n=6), 5-(n=6), 14-(n=6) and 28-days (n=4) after induction of diabetes. Note the progressive increase in R2* values, suggesting increased levels of hypoxia over the 4 week period.

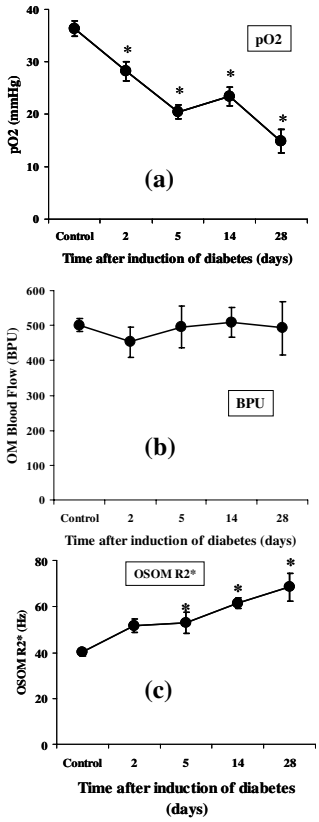

*p<0.05 compared to control

Figure 2

DISCUSSION AND CONCLUSION: These preliminary results suggest that hypoxic changes can occur very early in the etiology of diabetes (Fig. 2.a), and at least these early changes are not related to regional blood flow changes (Fig. 2 (b)). These observations are consistent with previous reported measurements made with microelectrodes at 3 mm depth of kidney [5]. The progressively increasing R2* in medulla is consistent with OxyLite measurementsand hence support the feasibility of using BOLD MRI in identifying changes in renal hemodynamics in diabetics early in the disease process. Further studies are warranted to extend the findings from these cross-sectional studies to longitudinal studies. Further studies are also necessary to understand the underlying mechanisms that lead to enhanced hypoxia and investigate if it can be reversed by pharmacologic interventions.

ACKNOWLEDGEMENTS: Work was supported in part by a pilot grant funding from ENH (ES), and a grant from the National Institutes of Health, DK-53221 (PVP).

REFERENCE: 1. Scand J Clin Lab Invest, 1986. 46(3): 201-6. 2. Hypertension, 1996. 28(1):127-32. 3.Diabetes, 1994. 43(5):629-33. 4. Intern Med, 2004. 43(1):9-17. 5. Diabetologia, 2003. 46(8):1153-60. 6. J Magn Reson Imaging, 2003. 17(1):104-13. 7. Circulation, 1996. 94(12):3271-5. 8.J Magn Reson Imaging, 1997. 7(6):1163-5. 9. Kidney Int, 1999. 55(1):294-8. 10. J Magn Reson Imaging, 2001. 13(5):744-7. 11. J Magn Reson Imaging, 1999. 9(6):842-6. 12. Diabetes Care, 2002. 25(3):575-8. 13. J Magn Reson Imaging, 2003. 17(6):671-5. 14. J Magn Reson Imaging, 2004. 19(5):610-6. 15. J Magn Reson Imaging, 2004. 20(5):901-4. 16. J Magn Reson Imaging, 2005. 21(3):245-8.