Application of Magnetic Resonance Direct Thrombus Imaging for the Detection and Monitoring of Pelvic Endometriosis

R. Taneja[1], G. Leung[1], S. Crisp[1], R. Bitar[1,2], D. Howe[3], P. Murphy[3], A. R. Moody[1,2]

[1]Department of Medical Imaging, Sunnybrook and Women's College Health Sciences Centre, Toronto, Ontario, Canada, [2]Department of Medical Imaging, University of Toronto, Toronto, Ontario, Canada, [3]Pfizer Global Research and Development, Pfizer Inc., Sandwich, Kent, United Kingdom

Introduction: Endometriosis is a disease in which endometrial tissue implants and grows outside of the uterus. Symptoms include cyclical pelvic pain and infertility. Endometriosis is estimated to affect 10-15% of women of reproductive age, yet only 5% are investigated and given a definitive diagnosis. Part of the reason for this is that diagnosis requires a surgical procedure (laparoscopy) to inspect the pelvic peritoneum, and although this is relatively safe it is not without risk and cost. A non-invasive diagnostic procedure would be preferable.

It has been reported that endometrial foci contain iron in various states[1]. MRI methods developed for studying vascular thrombi may be useful to locate and characterise this iron within endometrial lesions. *Magnetic Resonance Direct Thrombus Imaging* (MRDTI) uses a highly T1-weighted acquisition to visualise methaemoglobin–rich thombi whilst suppressing surrounding sources of high signal intensity[2]. We hypothesise that the same core MRDTI approach can be applied to the female pelvis to locate blood products within endometrial lesions.

A number of publications have described high signal intensity features on standard T1WI as attributable to endometriosis[3-5]. These studies focused primarily on large ectopic lesions such as those arising in the ovaries or the rectovaginal space. A key challenge will be to detect and visualise small lesions located in the peritoneum. Studying large lesions however will be important during development to optimise contrast.

In this study, MRDTI has been applied to women with a presumptive diagnosis of endometriosis scheduled to undergo laparoscopy to assess the ability of the approach to detect and describe endometrial implants.

Methods: For MRI, patients were scanned using a 1.5T GE TwinSpeed MR Scanner (GE Medical Systems, USA) using an 8-channel torso-pelvis phased-array coil (USA Instruments, USA). The MRDTI imaging was performed in the coronal plane with slices centred on the uterus. The MRDTI approach utilises a 3D T1W fat-suppressed spoiled gradient echo sequence (TR/TE/α 5.8ms/2.7ms/15°), with 2.4mm slice thickness, FOV 420 x 420mm^2, matrix size 320 x192, and effective voxel size 1.3mm x 2.2mm x 2.4mm. Fat suppression was performed using the *SPECIAL* (SPECtral Inversion At Lipids) GE proprietary technique. Patients were scanned during free breathing, acquiring 3 volumes, each of 1 NEX and using non-rigid registration to correct for inter image motion[6]. Standard T1 and T2W acquisitions were also performed.

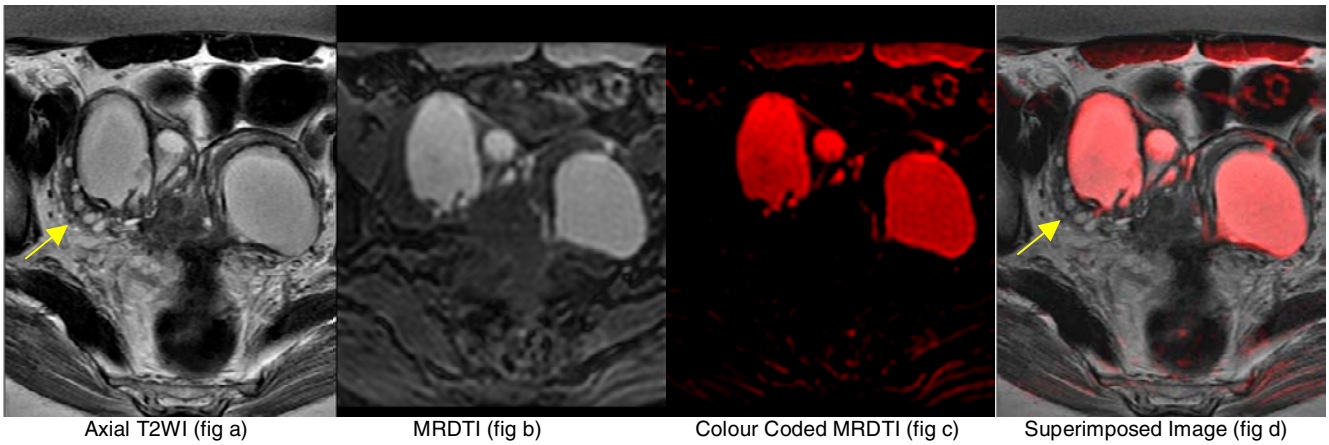

Axial T2WI (fig a) MRDTI (fig b) Colour Coded MRDTI (fig c) Superimposed Image (fig d)

Results: Using the MRDTI technique, endometriotic foci were visualised as uniformly bright (fig b). Obtaining high resolution MRDTI images with superimposition onto T2WI improved anatomical localisation (fig d). Superimposition is also useful in the differentiation of endometriotic foci from other cystic lesions in the vicinity that appear bright on T2WI (fig a and fig d, arrows).

Discussion: Detecting small ectopic lesions in the pelvis presents a challenge. Even with the bright signal arising from the paramagnetic iron, the main limitation of standard T1-weighted imaging is that the bright foci appear adjacent to other sources of high signal intensity such as lipid or flowing blood. The MRDTI approach aims to suppress these sources of bright signal leaving only aqueous foci with a short T1 visible. High Resolution and three-dimensional image acquisition aid in visualisation of small endometriotic foci. Superimposition of these images onto T2WI improves lesion localisation.

Conclusion: Our initial experience using the MRDTI sequence in patients with suspected endometriosis has shown it to be promising in the assessment of disease burden and detection of small lesions. Further, the technique may have a potential role in the assessment of response to therapy and provide a reliable and non-invasive means of diagnosing, quantitating and following up endometriosis.

References:

1. Van Langendonckt A *et al.* Fertility and Sterility 2002; 78:712
2. Moody AR *et al.* Circulation 2003; 107 : 3047
3. Stratton P *et al.* Fertility and Sterility 2003; 79 : 1078
4. Bazot M *et al.* Radiology 2004; 232 : 379
5. Spaczynski *et al.* Sem. Repro. Med. 2003; 21 : 193
6. Leung et al. Proc ISMRM 2005; 2230 : 436