High Field Body Imaging: A Clinical Perspective

Robert R. Edelman, M.D., Dept. of Radiology, Evanston Northwestern Healthcare
Professor of Radiology, Northwestern University School of Medicine

Objectives

- Review basic principles underlying the 3T MR image acquisition:
  pulse sequences, bandwidth, SNR, CNR, echo spacing and train length, spatial resolution
- Consider field strength-related issues:
  susceptibility, SAR, chemical shift, variation in relaxation parameters, RF coils
- Review special imaging techniques, clinical applications and limitations of 3T MRI in the body

Since the first use of clinical MR imaging, there has been a continuous trend towards the use of higher field systems. Early in the clinical MRI era, systems ranged from less than 0.1 Tesla to as high as 0.6 Tesla. While there is a sizeable market for open architecture low field 0.2T – 0.35T system, and more recently for open 0.7T systems, the best quality images have typically come from "high field" 1.5 Tesla systems. Even higher field systems, typically at 3T and 4T but nowadays as high as 9.4T, have been used for brain imaging research. Only recently have 3T systems come into routine clinical use and included body RF coils so that non-neuro imaging is feasible.

Although there are many similarities in the function of 3T and 1.5T systems, there are also substantial differences that must be taken into account to avoid image artifacts and to maximize the clinical capabilities of the system.

Strengths of Body MRI at 1.5T

- Sensitive and specific for liver metastases, vascular pathology, etc.
- Time-efficient in cooperative subjects

Weaknesses

- Not always sensitive for very small or subtle lesions => e.g. early pancreatic cancer, microscopic liver metastases, distal renal artery stenoses
- Problematic if patient unable to hold breath
- Fat suppression may be imperfect

General Considerations at 3T

- SNR ~ 2x neglecting physiological noise and bandwidth issues
- Increased magneto-hydrodynamic effect
- T1 relaxation times are longer
- T2 and T2* are shorter
- Contrast agent efficacy?
- Chemical shift and susceptibility artifact is 2x
- RF power deposition is ~4x
- Less homogeneous RF field
- Fewer RF coils are available
- More safety issues

- Cost

<u>Field Strength-Related Parameters and Relationship to Image Quality</u>

- Gradients
- RF coils
- Pulse sequence
- Signal-to-noise and contrast-to-noise ratios
- Voxel (= slice thickness * FOV/Nf * FOV/Np)
- Sampling bandwidth (e.g. 10kHz – 250kHz)
- TR/TE/flip angle
- Specific absorption rate

<u>Bandwidth Considerations at Lower Field</u>

- Lower intrinsic SNR
- SNR proportional to 1/sqrt(BW)

  => can use lower BW readout to improve SNR

  * *but, lower BW => longer TE and TR*

SNR Issues

SNR ~ theoretically 2x neglecting physiological noise and bandwidth issues

BUT:

Higher physiological noise

Shorter T2/increased chemical shift requiring higher BW

Reduced multi-slice efficiency from SAR limit

Reduced flip angle for SSFP/MRA/FSE from SAR limit (impairs tissue contrast)

New head and body array coils have 8 or more elements

- ⇨ additional 40% or more improvement beyond the two-fold benefit of 3T
- ⇨ improved parallel imaging

Tissue Contrast

T1 relaxation times are longer

⇒ Impact on lesion appearance?

Diminished T1 contrast using SPGR/FLASH

⇒ Use IR prepped-SPGR (FIRM/turboFLASH/MP-RAGE)

- ➢ Motion insensitivity (single shot acquisition)
- ➢ Different tissue contrast

T2 and T2 are shorter*

⇒ Need shorter echo trains

⇒ Confounded by SAR limits if using short refocusing RF pulses

⇒ Blurring + SNR hit (use parallel imaging)

⇒ More sensitive for organ iron?

Contrast Agents

- **Gadolinium chelates:**
  => Relaxivity (probably not major issue compared with 1.5T for standard chelates)
  => Longer T1s increase background suppression
  => Permits use of lower dose (typically half of that required at 1.5T)
- **Iron particles:**
  => Higher relaxivity
  => Shorter T2 may reduce dynamic range of effect

B0 and B1 Issues for Body MRI at 3T

- Chemical shift and susceptibility artifact are 2x
- RF power deposition is ~4x
- Blooming of gas-containing bowel loops
- More artifact with FIESTA/trueFISP
- Need higher readout BW to minimize susceptibility and chemical shift
- Inverse correlation of minimum TE and flip angle for RF excitation (limits SSFP, MRA)
- Shorter duration of fat sat pulses and more uniform fat suppression
- Faster cycling of out of phase and in phase TE gives less flow artifact and more slices (aside from SAR limit)

Safety Concerns

- Increased magneto-hydrodynamic effect
  => Peaked T-wave during rapid systolic blood flow
  => May require peripheral gating
  => ECG more difficult to interpret for unstable pt
  => Vector ECG gating may be effective solution

- Increased risk of RF burns from ECG leads/RF coils/implanted wires
- Increased torque on ferromagnetic implants
- 6dB intrinsic increase in acoustic noise, compounded by need for stronger gradients to achieve short TE or short echo trains

Conclusions

- Body imaging at 3T is feasible and often better than at 1.5T (with notable exception of cardiac)
  => Technique optimization must take into account:
    - SAR limitations
    - Relaxation times
    - SNR
- May use different imaging techniques
  - Magnetization-prepared single shot (to overcome lower T1 contrast at 3T)
  - Parallel MRI
  - Hyperechoes for turbo/fast spin-echo acquisition (to reduce SAR)

- Non-selective RF excitation (e.g. “EasyStep”) for contrast-enhanced MRA with reduced power deposition

- Fat suppression more effective at 3T
- Certain artifacts can be worse at 3T (e.g. B1 inhomogeneity)
- Functional imaging more effective at 3T (BOLD, ASL)

Figure 1A. 1.5 tesla delayed post-contrast fat-suppressed 3D acquisition.

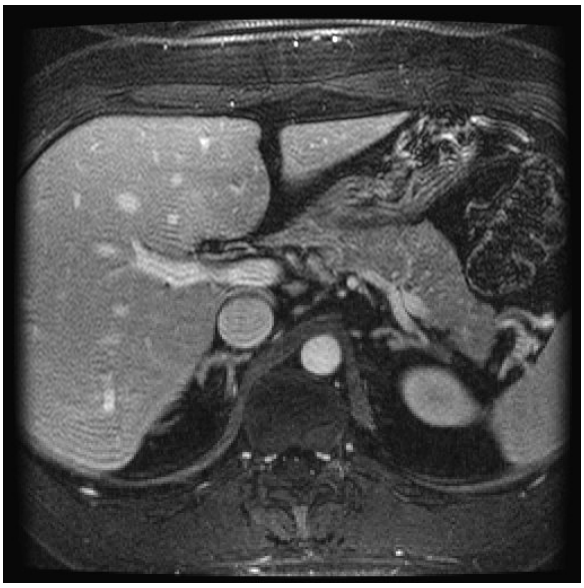

Figure 1B. Corresponding image at 3 tesla. Note that image quality for the blood vessels and visualized abdominal organs is markedly improved at the higher field strength due to an approximately two-fold increase in SNR.

Suggested Readings

Wolfsberger S, Ba-Ssalamah A, Pinker K, et al. Application of three-Tesla magnetic resonance imaging for diagnosis and surgery of sellar lesions. J Neurosurg 2004; 100: 278- 286.

Barth M, Nobauer-Huhmann I, Reichenbach J, et al. High-resolution three-dimensional contrast-enhanced blood oxygenation level-dependent magnetic resonance venography of

brain tumors at 3 Tesla: first clinical experience and comparison with 1.5 Tesla. Invest Radiol 2003; 38: 409- 414.

Graf H, Schick F, Claussen C, Seeman M. MR visualization of the inner ear structures: comparison of 1.5 Tesla and 3 Tesla images. Rofo Fortschr Geb Rontgenstr Neuen Bildgeb Verfahr 2004; 176: 17- 20.

Sosna J, Rofsky N, Pedrosa I, et al. MR imaging of the prostate at 3-Tesla: comparison of an external phased array coil to imaging with an endorectal coil at 1.5 Tesla. Acad Radiol 2004; 11: 857- 862.

Tanenbaum L. 3T MRI in clinical practice. Appl Radiol 2005; 34: 8-17.

Ludescher B, Martirosian P, Lenk S, et al. High-resolution magnetic resonance imaging of trabecular bone in the wrist at 3 tesla: initial results. Acta Radiol (2005 May) 46(3):306-9.

Takahashi M, Uematsu H, Hatabu H. MR imaging at high magnetic fields. Eur J Radiol 2003; 46: 45-52.

Trattnig S, Ba-Ssalamah A, Noebauer-Huhmann I, et al. MR contrast agent at high field MRI (3 Tesla). Top Magn Reson Imaging 2003; 14: 365- 375.

Martin DR, Friel HT, Danrad R, De Becker J, Hussain SM. Approach to abdominal imaging at 1.5 Tesla and optimization at 3 Tesla. Magn Reson Imaging Clin N Am (2005 May) 13(2):241-54, v-vi

Collins CM, Liu W, Schreiber W, Yang QX, Smith MB. Central brightening due to constructive interference with, without, and despite dielectric resonance. J Magn Reson Imaging. 2005 Feb;21(2):192-6.

Alsop D, Watkins R, Greenman R, Schenck J, Lenkinski R. In-vivo mapping of B1 uniformity produced by a whole body 3T RF coil. Proc Intl Soc Mag Reson Med 9 2001; 1094.