Evaluation (Function, Ischemia) of Stem Cell Therapy Patients

Michael Jerosch-Herold, PhD
Oregon Health & Science University, Portland, OR

Stem Cells and Myocardial Repair

- Stem cells: ability to self-renew and form differentiated cell types
- Sources: embryonal and adult stem cells
  - Bone marrow derived (progenitor) stem cells (BMSC) provide autologous source
  - BMSC engraftment leads to new vessel formation in infarcted myocardium.
  - Mechanisms leading to benefits largerly unknown or controversial.

Applications of Myocardial Stem Cell Implantation

- In patients with acute MI or chronic angina
  - After successful reperfusion
- Potential benefits
  - Improvement of regional perfusion and function.
  - Changes in infarct remodeling

Transmural Extent of Infarction and Improvement in Regional Function after Bone Marrow-Derived Stem-Cell (BMSC) Transfer

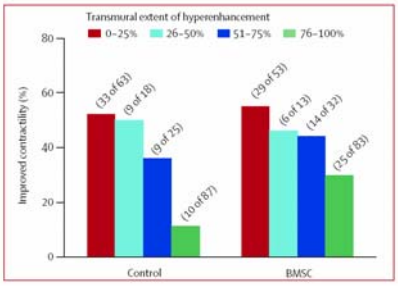

Janssens S, et al, Lancet. 2006 Jan 14;367(9505):113-21.

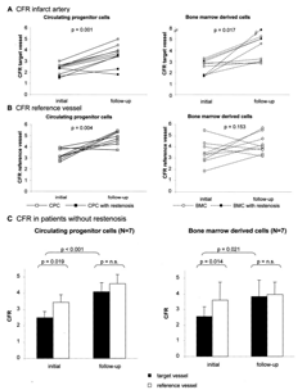

Coronary flow reserve (CFR) in response to 2.4 mg/min adenosine IC in the infarct artery (target vessel, upper panel, A) and in the reference vessel (lower panel, B) immediately before progenitor cell therapy and at 4-month follow-up

TOPCARE AMI Study: Assmus, B. et al. Circulation 2002;106:3009-3017

Potential Role of CMR in Evaluation of Stem Cell Therapy

- Delayed contrast enhancement for infarct sizing
- Cine MRI (w/ or w/o spatial modulation of magnetization for assessment of ventricular function and ventricular remodeling
- Myocardial perfusion imaging to assess angiogenesis

Rapid Assessment of Regional Myocardial Function

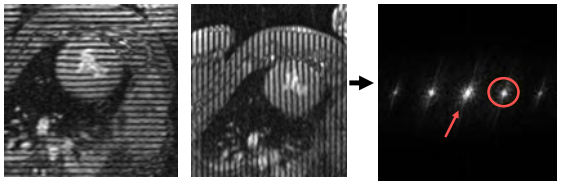

- HARP speeds up the analysis of myocardial strain analysis
- Was used for assessment of regional function in canine infarct model, pre and post stem cell transfer

E_{rr} strain map



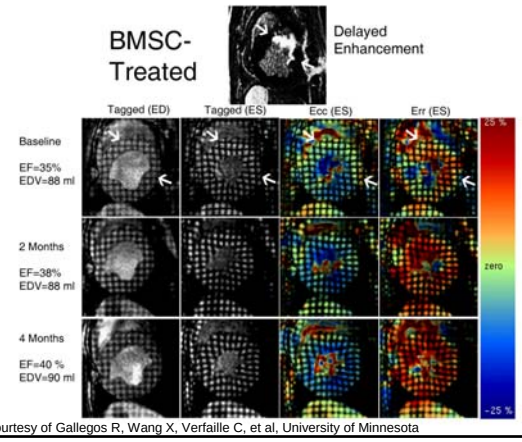

Courtesy of Gallegos R, Wang X, Verfaille C, et al, University of Minnesota

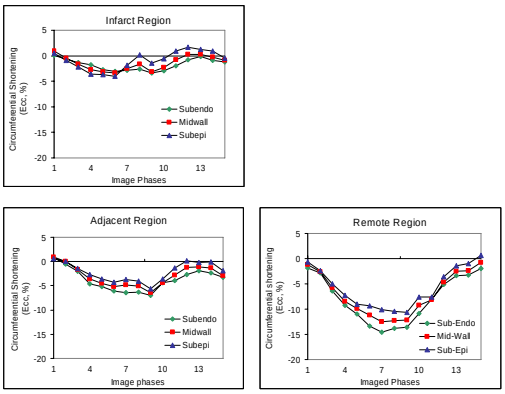

Courtesy of Gallegos R, Wang X, Verfaille C, et al, University of Minnesota

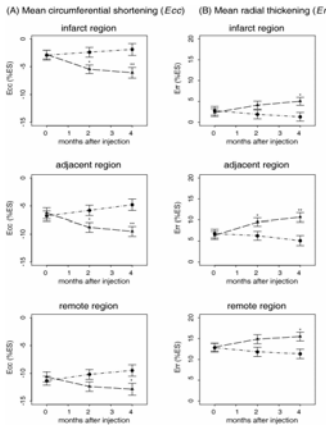

The time course of the changes of end-systolic myocardial strain: circumferential shortening (*Ecc*) (A), radial thickening (*Err*) (B) in myocardial infarct, adjacent and remote regions in control (n=5) and BMSC-treated (n=5) animals at baseline, and follow-ups at 2 and 4 months post-BMSC injection, respectively.

Dashed line indicates BMSC-treated group, dot-dashed line indicates control group. (*P<0.03 versus control group, **p<0.001 versus control group)

Perfusion and Metabolism

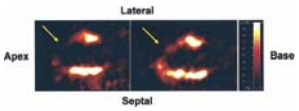

18F-FDG-positron emission tomography (PET) before and 3 months after cell therapy in a 30-year-old male patient with an 8-month-old anteroapical infarction.
From: Strauer BE, et al, The IACT Study, JACC 46(9), 1651-1658 (2005).

- Stem cell therapy in patients improved myocardial glucose metabolism (PET)

MRI Perfusion Assessment

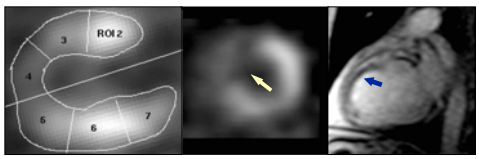

N 13 PET (21.5 mCi N13) **FDG PET** **First Pass Gd-DTPA Enhanced MRI**

- Spatial resolution sufficient for endo/epi differentiation
- Absolute blood flow can be estimated

Evaluation of Function and Ischemia for Stem Cell Therapy with MRI

- Application of CMR for stem cell therapy has been mostly confined to experimental studies
- Exceptions: cine and DCE MRI in recent clinical trial in patients
  - Janssens S, et al, Lancet. 2006 Jan 14;367(9505):113-21.